











Cestrum axillare hepatotoxicity in cattle in the Distrito Federal, Goiás and Minas Gerais¹

Ana Livia V. Sousa² , Davi E.R. Sousa^{2,3} , Liz A. Cerqueira^{2,3} ,
Cintia R.R. Queiroz-Machado⁴ , Paula R. Giaretta⁵ , Franklin Riet-Correa⁶ ,
Márcio B. Castro^{2,3}  and Mizael Machado^{3,7*} 

ABSTRACT. - Sousa A.L.V, Sousa D.E.R, Cerqueira L.A, Queiroz-Machado C.R.R., Giaretta P.R., Riet-Correa F., Castro M.B. & Machado M. 2024. *Cestrum axillare* hepatotoxicity in cattle in the Distrito Federal, Goiás and Minas Gerais. *Pesquisa Veterinária Brasileira* 44:e07399, 2024. Plataforma de Investigación en Salud Animal, Instituto Nacional de Investigación Agropecuaria, Estación Experimental del Norte, Ruta 5 Km 386, Tacuarembó 45000, Uruguay. E-mail: mmachado@inia.org.uy

This study reports four outbreaks of *Cestrum axillare* poisoning in cattle. Outbreaks occurred in farms of the Distrito Federal, Goiás, and Minas Gerais states during the dry season, affecting cows and heifers, with a mortality rate of 1 to 14,28%. Poisoned animals showed neurological signs and recumbency, followed by death within 12 hours, and some animals were found dead. Gross and histological lesions were typical of acute hepatotoxicity with hepatomegaly, enhancement of lobular pattern, and centrilobular to massive necrosis. This study seems to be the first report on *C. axillare* poisoning in cattle in the Distrito Federal, Goiás, and Triângulo Mineiro. *C. axillare* poisoning must be included in the differential diagnosis for cattle with hepatic necrosis in these locations.

INDEX TERMS: Poisonous plants, cattle, hepatotoxicosis, *Cestrum axillare*.

RESUMO. - [Hepatotoxicidade do *Cestrum axillare* em bovinos do Distrito Federal, Goiás e Minas Gerais.] Este estudo relata quatro surtos de intoxicação por *Cestrum axillare* em bovinos. Os surtos ocorreram em fazendas do Distrito Federal, Goiás e Minas Gerais durante a estação

seca, afetando vacas e novilhas, com taxa de mortalidade de 1 a 14,28%. Os animais afetados apresentaram sinais neurológicos e decúbito, seguidos de óbito em 12 horas. Alguns animais foram encontrados mortos. Foram observadas lesões macroscópicas e histológicas típicas de hepatotoxicidade aguda como hepatomegalia, evidenciação do padrão lobular e necrose centrolobular a massiva. Este é o primeiro relato de intoxicação por *C. axillare* em bovinos no Distrito Federal, Goiás e Triângulo Mineiro. A intoxicação por *Cestrum axillare* deve ser incluída no diagnóstico diferencial de bovinos com necrose hepática nessas localidades.

TERMOS DE INDEXAÇÃO: Plantas tóxicas, bovinos, hepatotoxicidade aguda, *Cestrum axillare*.

INTRODUCTION

Cestrum axillare (sin. *Cestrum laevigatum*) is a shrub plant of America from the Solanaceae family that can reach up to two meters in height, with an erect stem, elliptical and oval leaves with a stalked insertion, and an axillary arrangement. Flowers are white with sessile insertion of lanceolate petals, and fruits are black (Vignoli-Silva & Mentz 2020). The plant occurs mainly in the Southeast, Midwestern, and Northeast Brazil (Tokarnia et al. 2012).

¹ Received on November 8, 2023.

Accepted for publication on December 9, 2023.

² Laboratório de Patologia Veterinária (LPV), Faculdade de Agronomia e Medicina Veterinária (FAV), Universidade de Brasília (UnB), Via L4 Norte, Asa Norte, Brasília, DF 70636-200, Brazil.

³ Graduate Program in Animal Science, Faculdade de Agronomia e Medicina Veterinária (FAV), Universidade de Brasília (UnB), Campus Darcy Ribeiro, ICC Norte, Asa Norte, Brasília, DF 70910-900, Brazil.

⁴ CENUR Noreste, Universidad de la República (UdelaR), Ruta 5 Km 386, Tacuarembó 45000, Uruguay.

⁵ Gastrointestinal Laboratory, Department of Small Animal Clinical Sciences, College of Veterinary Medicine and Biomedical Sciences, Texas A&M University, College Station, TX, USA.

⁶ Graduate Program in Animal Science in the Tropics (PPGCAT), Faculdade de Medicina Veterinária e Zootecnia, Universidade Federal da Bahia (UFBA), Av. Adhemar de Barros 500, Ondina, Salvador, BA 40170-110, Brazil.

⁷ Plataforma de Investigación en Salud Animal (PSA) (PSA), Instituto Nacional de Investigación Agropecuaria (INIA), Estación Experimental del Norte, Ruta 5 Km 386, Tacuarembó 45000, Uruguay. *Corresponding author: mmachado@inia.org.uy

The history of *C. axillare* poisoning is very interesting. The first evidence of *C. axillare* toxicity was suspected when the plant was introduced as an ornamental plant in many farms in South Africa (Thorburn 1934, Tokarnia et al. 2012). The poisoning was observed in ruminants near the river Chase and was named Chase Valley Disease, but the cause remained unknown for many years (Thorburn 1934). Recently, a toxic compound containing kaurene glycoside carboxyparquin was demonstrated within young and mature leaf samples of *C. axillare* (Ubiali et al. 2022).

Cestrum axillare poisoning occurs mainly under forage scarcity, during the dry season, or when the plant is sprouting due to its low palatability (Tokarnia et al. 2012, Ubiali et al. 2022, Riet-Correa et al. 2023). Clinically, animals poisoned by this plant present signs between 15 and 24 hours after ingestion related to acute hepatic failure and hepatic encephalopathy, such as lethargy, anorexia, ruminal atony, and neurological disturbance. Death can occur between six and 48 hours after the first clinical signs onset (Tokarnia et al. 2012, Ubiali et al. 2022). *Cestrum axillare* poisoning is pathologically characterized by the enhancement of hepatic lobular pattern with centrilobular to massive hepatocellular necrosis and hemorrhage (Tokarnia et al. 2012).

In Brazil, spontaneous poisonings have been reported in cattle (Döbereiner et al. 1969, Silva & Silva Júnior 1996, Purisco et al. 1998, Coutinho et al. 2013, Santos et al. 2016, Oliveira Neto et al. 2017, Ubiali et al. 2022), and rarely in buffaloes (Barbosa et al. 2010, Ubiali et al. 2022) and goats (Peixoto et al. 2000, Brito et al. 2010, Ubiali et al. 2022). Experimental poisonings by *C. axillare* have been performed in cattle (Thorburn 1934, Tokarnia 1965, Döbereiner et al. 1969, Couto 1970, apud Nunes 1972, Van Der Lugt et al. 1991, Oliveira Neto et al. 2017), buffaloes (Barbosa et al. 2010), goats (Thorburn 1934, Menezes 1990, Peixoto et al. 2000, Marinho et al. 2018), sheep (Thorburn 1934, Van Der Lugt et al. 1992), and rabbits (Barros & Döbereiner 1968). In horses, pigs, birds (Thorburn 1934), guinea pigs (Thorburn 1934, Barros & Döbereiner 1968), mice, and rats (Barros & Döbereiner 1968), experimental administration of *C. axillare* failed to cause poisoning.

Experimental toxic doses for cattle ranging from 10 to 50g/kg of body weight (BW) of sprouting or mature leaves of *C. axillare* were reported in Rio de Janeiro (Tokarnia 1965, Döbereiner et al. 1969), and with fresh leaves, shoots, and fruits in Minas Gerais and Paraíba (Nunes 1972, Oliveira Neto et al. 2017). Toxic doses of *C. axillare* for buffaloes range from 20 to 40g/kg of BW of fresh leaves (Barbosa et al. 2010) and 30g/kg of BW of sprouts, fresh leaves, and mature leaves (Menezes 1990, Peixoto et al. 2000), and 10g/kg BW of dry leaves (Marinho et al. 2018) for goats. In sheep, the toxic dose ranges from 2.5 to 10g/kg of BW of dry *C. axillare*

leaves (Van Der Lugt et al. 1992), and a dose of 70g/kg of BW of fresh plant experimentally poisoned rabbits (Barros & Döbereiner 1968).

This study reports a series of cases of natural poisoning by *C. axillare* in Midwestern and Southeastern Brazil and briefly reviews the poisoning.

MATERIALS AND METHODS

Animal Ethics. All information and samples were obtained from records of the Veterinary Pathology Laboratories of cattle that had natural death by acute poisoning by *Cestrum axillare*.

Epidemiological and clinical data regarding four selected *Cestrum axillare* poisoning outbreaks in cattle were obtained from veterinarians and livestock owners. The outbreaks were classified from A to D according to chronological order. Outbreaks A and D were recorded in Midwestern Brazil at Brasília (Distrito Federal) and Formosa (Goiás State) municipalities, respectively. Outbreaks B and C occurred in Southeast Brazil at Coromandel and Belo Horizonte municipalities (both in Minas Gerais State), respectively. In each outbreak, a necropsy of one poisoned cattle was performed at least, and organ samples were collected and fixed in a 10% buffered formalin, routinely processed and embedded in paraffin, sectioned at 4µm and slides stained with hematoxylin and eosin (HE) for evaluation under light microscopy. Additionally, data on clinical history, breed, sex, and age of the cattle were collected and recorded. Botanical samples collected from the paddock where the poisoning occurred in outbreak D were identified as *C. axillare* and deposited under number UB239101 at the “Departamento de Botânica” (Botany Department) of the “Instituto de Biologia” (Biology Institute) of the “Universidade de Brasília” (UnB).

RESULTS

Epidemiology and clinical signs

Epidemiological data are presented in Table 1. Shrubs of *Cestrum axillare* were observed in the paddocks where cattle grazed in outbreaks A, B, and C. In Outbreak D, there was a heavily invaded area (0.5-1.5 hectares) by adult specimens of *C. axillare* (Fig.1 and 2) with evidence of high consumption of the plant in the paddock where cattle grazed (Fig.3). We also noticed paths amidst the invaded area, evidencing the access to the plants by the animals. Clinical signs were observed in cattle from Outbreaks A and C, which comprised ataxia and prolonged recumbency. In the remaining outbreaks, all animals were found dead.

Gross and histological lesions

All poisoned animals showed hepatomegaly, an enhanced hepatic lobular pattern, and multifocal small white areas on the cut surface of the liver. Edema in the initial portion of the duodenum and hemorrhagic gallbladder were also observed.

Table 1. Epidemiological data on outbreaks of *Cestrum axillare* poisoning in cattle in the Distrito Federal (DF), Goiás (GO), and Minas Gerais (MG) States

Outbreaks	Date	Category	Breed	Clinical signs	Animals in the herd	Affected (%)	Location
A	June 2008	Cows	Nelore	Ataxia and death	300	3 (1.0 %)	Brasília/DF
B	September 2020	Heifers	Nelore	Death	21	3 (14.3 %)	Coromandel/MG
C	August 2021	Cows	Nelore	Recumbency, death within 12 hours	200	9 (4.5 %)	Belo Horizonte/MG
D	September 2021	Cows and heifers	Nelore	Death	1000	10 (1.0 %)	Formosa/GO



Fig.1-3. *Cestrum axillare* poisoning in cattle. Outbreak D. (1) Cluster of greenish-yellow sessile flower buds. (2) Sprouting from a branch where cattle had consumed the plant. (3) Note that only the aerial part of *C. axillare* remained after cattle consumed the plant.

In Outbreaks A and C, petechiae and suffusions were detected in the heart muscle, ruminal and intestinal serosae, and the diaphragm. Partially digested fruits and leaves of *C. axillare* amidst the ruminal content were observed in the necropsies of poisoned cattle in Outbreak C. Histologically, the liver of affected animals showed centrilobular to massive necrosis (Fig.4) surrounded by micro and macrovesicular degeneration of hepatocytes, multifocal areas of hemorrhage, and a mild infiltrate of neutrophils.

DISCUSSION

Spontaneous poisoning by *Cestrum axillare* in ruminants has been reported in Southeast and Northeast Brazil, in the states of Rio de Janeiro (Döbereiner et al. 1969, Peixoto et al. 2000, Barbosa et al. 2010, Brito et al. 2010), Espírito Santo (Ubiali et al. 2022), São Paulo (Ubiali et al. 2022), Pernambuco (Silva & Silva Júnior 1996, Coutinho et al. 2013), Bahia (Santos et al. 2016, Ubiali et al. 2022) and Paraíba (Oliveira Neto et al. 2017). Experimental studies with *C. axillare* poisoning in cattle were performed with the plant collected in Ribeirão das Neves (MG) (Nunes 1972) and another one investigating the toxic principle in leaves of *C. axillare* collected in outbreaks of spontaneous poisoning in cattle in Esmeraldas (MG) (Marinho et al. 2018). Since 1960, spontaneous outbreaks of *C. axillare* poisoning in cattle have been reported close to the metropolitan mesoregion of Belo Horizonte (MG) (Ubiali et al. 2022). Our findings strengthen the first reports of *C. axillare* poisoning in cattle in the metropolitan mesoregion of Belo Horizonte (MG) and the persistence of the plant in the same area as a risk for cattle poisoning. In the Midwest region, there are anecdotal reports of the poisoning in cattle in Mato Grosso do Sul, but spontaneous outbreaks have not yet been reported (Purisco et al. 1998, Furlan et al. 2012). Although *C. axillare* occurs in Goiás State and the Distrito Federal (Vignoli-Silva & Mentz et al. 2020), poisoning of ruminants in these regions had not been previously reported.

All outbreaks of *C. axillare* poisoning in Brazil's Midwestern and Southeastern regions occurred during the dry season. As epidemiological findings observed in investigated outbreaks, *C. axillare* does not have good palatability. However, the plant

remains green in the dry season with a low supply of forage, leading to ingestion of the plant and intoxication (Tokarnia et al. 2012, Ubiali et al. 2022). In addition, heavily invaded areas of the paddocks by the plant, as observed in Outbreak D, can also trigger intoxication (Döbereiner et al. 1969, Barbosa et al. 2010, Brito et al. 2010, Coutinho et al. 2013, Santos et al. 2016, Oliveira Neto et al. 2017, Ubiali et al. 2022) or when the plant is the only forage available (Peixoto et al. 2000).

In this study, the diagnosis of *C. axillare* poisoning in cattle was based on the consumption and presence of the plant in paddocks where the animals grazed, clinical signs, and pathological findings. Clinical presentation of poisoned animals in Outbreaks A and C was restricted to neurological signs and recumbency followed by death within 12 hours.

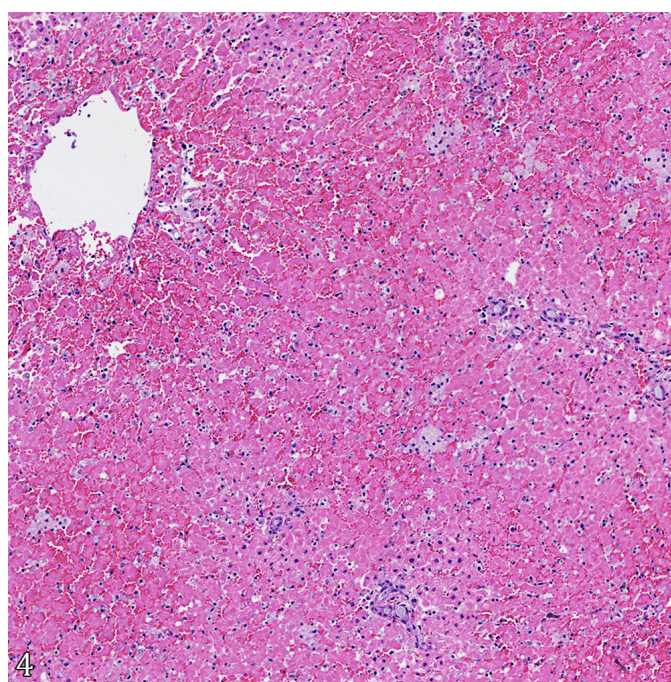


Fig.4. *Cestrum axillare* poisoning in cattle. Outbreak C. Massive hepatocellular necrosis associated with hemorrhage and mild ductular reaction. HE, obj. 40x.

This poisoning has been previously characterized by acute toxic hepatic damage with non-specific clinical signs such as apathy, anorexia, ruminal atony, abdominal pain, rectal tenesmus, sweating, dehydration, and neurological signs related to hepatic encephalopathy, such as motor incoordination, generalized muscle tremors, and aggressiveness. Affected animals also presented blindness, lateral recumbency, and coma in the terminal phase (Santos et al. 2008). The death may occur six to 48 hours after the first clinical signs (Ubiali et al. 2022).

Gross and microscopic findings of acute hepatotoxicity in cattle evaluated in the outbreaks investigated were similar to those already reported, characterized by hepatomegaly, enhancement of the hepatic lobular pattern, centrilobular to massive coagulative hepatic necrosis and degeneration, and hemorrhage (Oliveira Neto et al. 2017, Ubiali et al. 2022, Guizelini et al. 2022). Steroidal saponins and the kaurene glycosides parquin and carboxyparquin have previously been identified in *C. axillare* (Begum & Goyal, 2007, Ubiali et al. 2022). While saponins and parquin are unlikely to be responsible for the lesions in the liver, carboxyparquin may be the compound causing the hepatotoxicity herein described (Ubiali et al. 2022).

In general, *C. axillare* poisoning has a low incidence in Brazil that can be justified by the low palatability of the plant, variable toxic doses, and high lethal doses (Tokarnia 1965, Döbereiner et al. 1969, Couto 1970, apud Nunes 1972, Barbosa et al. 2010, Brito et al. 2010, Coutinho et al. 2013, Oliveira Neto et al. 2017). Since *C. axillare* was not toxic to cattle in the fructification stage, the plant stage's toxicity may be considered a variable factor (Thorburn 1934). Another factor implicated in cattle poisoning by *C. axillare* includes differences in the ingestion of the plant between naïve animals and native cattle born where the plant grows. Naïve cattle are more prone to ingest the plant than native animals (Coutinho et al. 2013), but this finding has not been widely reported.

In Brazil, acute hepatotoxicity in ruminants occurs through the ingestion of several plants (Guizelini et al. 2022, Riet-Correa et al. 2023). *Xanthium strumarium* was the only hepatotoxic poisoning plant reported in Southeastern Brazil, where Outbreak B occurred, and it must be an important differential diagnosis. However, this outbreak of *C. axillare* poisoning occurred in a different region from the poisoning by *X. strumarium* in cattle, which is restricted to the banks of the Araguari River in Minas Gerais State (Machado et al. 2021).

CONCLUSION

This study showed that *Cestrum axillare* poisoning affects cattle in the dry season in the Distrito Federal and State of Goiás and Minas Gerais. This poisoning may impact cattle herds in these regions and has a broader distribution in Brazil than previously reported. Further efforts to detect new outbreaks of *C. axillare* poisoning, differential diagnosis, and the impact on cattle production remained to be determined. Studies that aim to identify the chemical compounds of *C. axillare* are important to determine the toxic doses and toxicological mechanisms.

Acknowledgments. - The authors would like to thank the "Coordenação de Aperfeiçoamento de Pessoal de Nível Superior" (CAPES) for partial financing of the study (Finance Code 001) and the support of the "Conselho Nacional

de Desenvolvimento Científico e Tecnológico" (CNPq) for the Research Productivity grant (MBC). MM is a researcher of the "Sistema Nacional de Investigadores" (SNI, ANII) of Uruguay. Special thanks to Dr. Regina Célia Oliveira, from the Botanical Department of the "Universidade de Brasília" (UnB), for identifying the plant.

Conflict of interest statement. - The authors declare that there are no conflicts of interest.

REFERENCES

- Barbosa J.D., Oliveira C.M.C., Pinheiro C., Lopes C.T.A., Marquiori D., Brito M.F., Yamasaki E.M. & Tokarnia C.H. 2010. Intoxicação por *Cestrum laevigatum* (Solanaceae) em bubalinos. *Pesq. Vet. Bras.* 30(12):1049-1052. <<https://dx.doi.org/10.1590/S0100-736X2010001200008>>
- Barros G.C. & Döbereiner J. 1968. Experimentos com *Cestrum laevigatum* Schlecht. em animais de laboratório. *Pesq. Agropec. Bras.* 3:307-311.
- Begum A.S. & Goyal M. 2007. Research and medicinal potential of the genus *Cestrum* (Solanaceae) – a review. *Phcog. Rev.* 1(2):320-332.
- Bruto M.F., França T.N., Oliveira L.I., Ramos A.S., Peixoto T.C. & Aragão A.P. 2010. Intoxicação espontânea por *Cestrum laevigatum* em um caprino no Rio de Janeiro: relato de caso. *Revta Bras. Med. Vet.* 32(1):55-57.
- Coutinho L.T., Costa N.A., Mendonça C.L., Afonso J.A.B., Riet-Correa F., Dantas A.F.M. & Silva N.A.A. 2013. Intoxicação natural de bovinos leiteiros por *Cestrum laevigatum* (Solanaceae) no agreste de Pernambuco Brasil. *Ciênc. Anim. Bras.* 14(3):352-359. <<https://dx.doi.org/10.5216/cab.v14i3.13476>>
- Couto E.S. 1970. Personal communication. In: Nunes L.P. 1972. Intoxicação experimental de bovinos por *Cestrum laevigatum* Schlecht. I. Sinais clínicos. II. Alterações no sangue, líquido cefalorraquidiano e urina. III. Alterações anatomo e histopatológicas. Tese de Mestrado, Universidade Federal de Minas Gerais, Belo Horizonte. 40p.
- Döbereiner J., Tokarnia C.H. & Canella C.F.C. 1969. Intoxicação por *Cestrum laevigatum* Schlecht, a causa de mortandades em bovinos no estado do Rio de Janeiro. *Pesq. Agropec. Bras.* 4:165-193.
- Furlan F.H., Colodel E.M., Lemos R.A.A., Castro M.B., Mendonça F.S. & Riet-Correa F. 2012. Poisonous plants affecting cattle in Central-Western Brazil. *Int. J. Pharmacogn. Phytochem. Res.* 2:1-13.
- Guizelini C.C., Lemos A.A.R. & Riet-Correa F. 2022. Plantas e micotoxinas hepatotóxicas, p.83-91. In: Riet-Correa F., Schild A.L., Lemos R., Borges J.R., Mendonça F.S. & Machado M. (Eds), *Doenças de Ruminantes e Equídeos*. Vol.2. 4th ed. Medvet, São Paulo.
- Machado M., Queiroz C.R.R., Wilson T.M., Sousa D.E.R., Castro M.B., Saravia A., Lee S.T., Armien A.G., Barros S.S. & Riet-Correa F. 2021. Endemic *Xanthium strumarium* poisoning in cattle in flooded areas of the Araguari River, Minas Gerais, Brazil. *Toxicon* 200:23-29. <<https://dx.doi.org/10.1016/j.toxicon.2021.06.019>> <PMid:34217747>
- Marinho J.B.R., Carvalho A.U., Pierezan F., Keller K.M., Riet-Correa F., Melo M.M. & Soto-Blanco B. 2018. Comparação dos efeitos das folhas de *Cestrum axillare* Vell. Com as saponinas isoladas em caprinos. *Pesq. Vet. Bras.* 38(5):852-861. <<https://dx.doi.org/10.1590/1678-5150-PVB-5244>>
- Menezes M.M. 1990. Alterações anatômico e histopatológicas da intoxicação experimental por *Cestrum laevigatum* Schlecht. em caprinos (*Capra hircus*). *Cad. Ômega, Sér. Vet.* (4):41-52.
- Nunes L.P. 1972. Intoxicação experimental de bovinos por *Cestrum laevigatum* Schlecht. I. Sinais clínicos. II. Alterações no sangue, líquido cefalorraquidiano e urina. III. Alterações anatomo e histopatológicas. Tese de Mestrado, Universidade Federal de Minas Gerais, Belo Horizonte, 40p.
- Oliveira Neto T.S., Riet-Correa F., Barbosa F.M.S., Silva C.M.B.A., Marques M.F.S., Nóbrega G.D., Simões S.V.D. & Lucena R.B. 2017. Natural and experimental poisoning by *Cestrum laevigatum* (Solanaceae) among cattle in the Agreste region of Paraíba, Brazil. *Semina, Ciênc. Agrárias* 38(5):3123. <<https://dx.doi.org/10.5433/1679-0359.2017v38n5p3123>>

- Peixoto P.V., Brust L.C., Duarte M.D., França T.N., Duarte V.C. & Barros C.S. 2000. *Cestrum laevigatum* poisoning in goats in Southeastern Brazil. *Vet. Human Toxicol.* 42(1):13-14. <PMid:10670079>
- Purisco E., Lemos R.A.A & Salvador S.C. 1998. Intoxicação por *Cestrum laevigatum*, p.319-321. In: Lemos R.A.A. (Ed.), Principais Enfermidades de Bovinos de Corte do Mato Grosso do Sul: reconhecimento e diagnóstico. Ed. UFMS, Mato Grosso do Sul.
- Riet-Correa F, Machado M. & Micheloud J.F. 2023. Plants causing poisoning outbreaks of livestock in South America: a review. *Toxicon*: X 17:100150. <<https://dx.doi.org/10.1016/j.toxcx.2023.100150>> <PMid:36747993>
- Santos J.C.A., Riet-Correa F, Simões S.V.D. & Barros C.S.L. 2008. Patogênese, sinais clínicos e patologia das doenças causadas por plantas hepatotóxicas em ruminantes e eqüinos no Brasil. *Pesq. Vet. Bras.* 28(1):1-14. <<https://dx.doi.org/10.1590/S0100-736X2008000100001>>
- Santos M.M., Sousa C.C.A., Menezes R.V., Figueiredo L.J.C., Costa J.N., Madureira K.M., Cunha-Fernandes V.A. & Peixoto T.C. 2016. Intoxicações por plantas em bovinos diagnosticadas pelo Centro de Desenvolvimento da Pecuária da Universidade Federal da Bahia, no período de 1985 a 2015. *Pesq. Vet. Bras.* 36(Supl.):187-189. (Resumo)
- Silva F.F. & Silva Júnior F.F. 1996. Intoxicação por *Cestrum laevigatum* Schlecht em bovinos na microregião de Garanhuns – PE. *Cad. Ômega Sér. Vet.*, (7):15-22.
- Thorburn J.A. 1934. Chase Valley disease: *Cestrum laevigatum* Schlecht., its toxic effects on ruminants. *Onderstepoort J. Vet. Sci. Anim. Indust.* 2(2):667-679.
- Tokarnia C.H. 1965. Alterações anátomo e histopatológicas da intoxicação de bovinos por *Cestrum laevigatum* Schlecht. Tese de Doutorado, Universidade Rural do Sul, Porto Alegre. 55p.
- Tokarnia C.H., Brito M.F., Barbosa J.D., Peixoto P.V. & Döbereiner J. 2012. Plantas/Micotoxinas que afetam o fígado, p.148-154. In: Ibid. (Eds), Plantas Tóxicas do Brasil. 2ª ed. Helianthus, Rio de Janeiro.
- Ubiali D.G., Lee S.T., Gardner D.R., Cook D., Pereira G.O. & Riet-Correa F. 2022. *Cestrum axillare* (Solanaceae) poisoning in ruminants. *Toxicon* 218:76-82. <<https://dx.doi.org/10.1016/j.toxicon.2022.09.005>> <PMid:36115412>
- Van Der Lugt J.J., Nel P.W. & Kitching J.P. 1991. The pathology of *Cestrum laevigatum* (Schlecht.) poisoning in cattle. *Onderstepoort J. Vet. Res.* 58(3):211-221. <PMid:1923385>
- Van Der Lugt J.J., Nel P.W. & Kitching J.P. 1992. Experimentally-induced *Cestrum laevigatum* (Schlecht.) poisoning in sheep. *Onderstepoort J. Vet. Res.* 59(2):135-144. <PMid:1513594>
- Vignoli-Silva M. & Mentz L.A. 2020. *Cestrum* in Flora do Brasil 2020. Jardim Botânico do Rio de Janeiro, Rio de Janeiro. Available at <<https://floradobrasil2020.jbrj.gov.br/reflora/floradobrasil/FB14636>> Accessed on Sep. 11, 2023.